

VirtaMed LaparoS™

Module descriptions - General Surgery v1.2

Learning objectives

- Selection of correct patient position and trocar placement according to the simulated procedure
- Correct identification of important anatomical landmarks and pathologies
- Efficient and safe use of laparoscopic instruments, including sponge holder, suction and irrigation device, monopolar and bipolar instruments, clip applicator and more
- Learning different resection and dissection techniques, as well as bleeding control and management of surgical complications
- Ambidextrous and non-dominant hand training using situs inversus totalis patient cases

Condensed training approach

The LaparoS™ training concept is focused on short sequences teaching transferable key skills. Each sequence takes place in a realistic environment and can be repeated according to the needs of the trainee until proficiency level is reached and stabilized, resulting in higher motivation and accelerated outcomes.

Instruments



Laparoscope



Atraumatic Grasper / Bipolar Kelly Grasper / Monopolar Kelly Grasper / Monopolar Electrode / Clip Applicator / Scissors / Surgical Sponge Holder / Suction and Irrigation Device

Contact the VirtaMed team to find out more:

+41 44 500 96 90

sales@virtamed.com

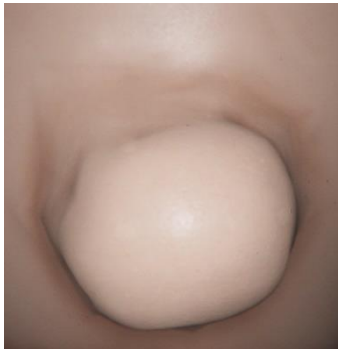
Guided/Unguided variant

For most of the training cases, there are two variants: guided and unguided training.

Guided: the current task to be accomplished is always displayed on the interface. Every step is guided with visual elements.

Unguided: The list of tasks to be accomplished is available on user request during the training. There are no guidance elements during the procedure or information messages.

Diagnostic Laparoscopy

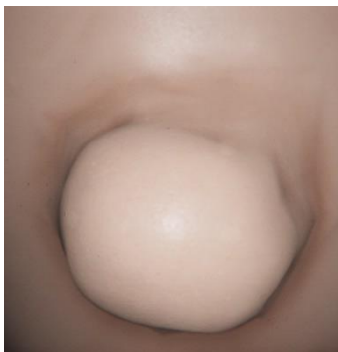


Unknown Pathology (Guided/Unguided)

A 45-year-old female presented with abdominal pain over a bulge in the abdominal wall of about 5x5 cm. Patient history indicates that the abdominal scar originates from a former stoma in the upper left quadrant of the abdomen. An incisional hernia at the location of the stomach is therefore suspected. Perform a diagnostic laparoscopy of the abdominal cavity to ensure that surrounding organs are healthy. Evaluate the extent of adhesions to the hernia defect to determine if a laparoscopic approach is indicated.

Learning objectives:

- Perform a clockwise diagnostic laparoscopy of the peritoneal cavity
- Use of the laparoscope to establish the optimal view of the hernia defect and surrounding tissue
- Adjustment of the patient's position to get a clear view of the operating field
- Addition of trocars as required for additional working instruments



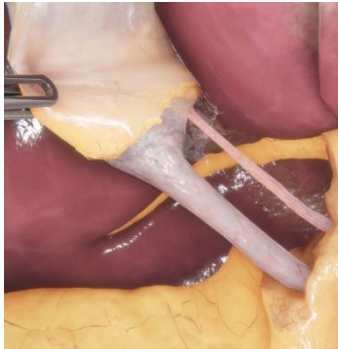Unknown Pathology Situs Inversus Totalis (Guided/Unguided)

A 45-year-old female presented with abdominal pain over a bulge in the abdominal wall of about 5x5 cm. Patient history indicates that the abdominal scar originates from a former stoma in the upper right quadrant of the abdomen. An incisional hernia at the location of the stomach is therefore suspected. Perform a diagnostic laparoscopy of the abdominal cavity to ensure that surrounding organs are healthy. Evaluate the extent of adhesions to the hernia defect to determine if a laparoscopic approach is indicated.

Learning objectives:

- Perform a counter-clockwise diagnostic laparoscopy of the peritoneal cavity
- Use of the laparoscope to establish the optimal view of the hernia defect and surrounding tissue
- Adjustment of the patient's position to get a clear view of the operating field
- Addition of trocars as required for additional working instruments

Exposure of Structures

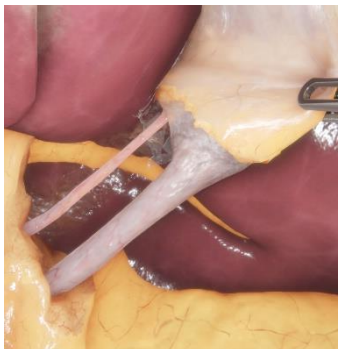

Hepatocystic Triangle (Guided/Unguided)

Safely expose and identify cystic duct and artery using both blunt and sharp dissection techniques.

Learning objectives:

- Retraction of the gallbladder to open the hepatocystic triangle
- Safe separation of the gallbladder from adhesions to establish a clear view
- Identification of the appropriate dissection plane
- Safe removal of tissue to expose the cystic duct and artery
- Correct use of tissue tension during dissection
- Use of the critical view of safety for secure ductal identification



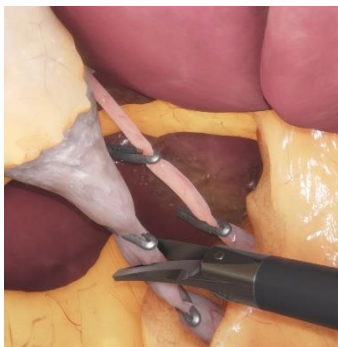Hepatocystic Triangle Situs Inversus Totalis (Guided/Unguided)

Safely expose and identify cystic duct and artery using both blunt and sharp dissection techniques.

Learning objectives:

- Safe handling of the electro-surgical instruments and safe blunt dissection using the non-dominant hand as the main operating hand
- Retraction of the gallbladder to open the hepatocystic triangle
- Safe separation of the gallbladder from adhesions to establish a clear view
- Identification of the appropriate dissection plane
- Safe removal of tissue to expose the cystic duct and artery
- Correct use of tissue tension during dissection
- Use of the critical view of safety for secure ductal identification

Clipping and Cutting

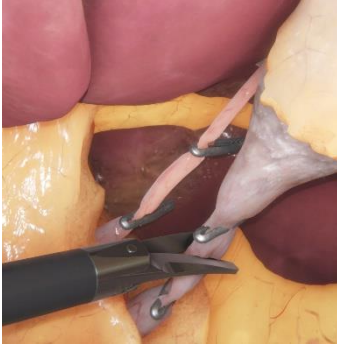

Cystic Pedicle Dissection (Guided/Unguided)

Safely identify and ligate the cystic duct and cystic artery.

Learning objectives:

- Correct visualization and identification of anatomical structures
- Safe placement of clips on the cystic duct and the cystic artery while visualizing the lower blade of the instrument
- Correct use of tissue tension when dissecting the cystic duct and cystic artery
- Verification that vessels have been correctly clipped to ensure safe resection of the gallbladder



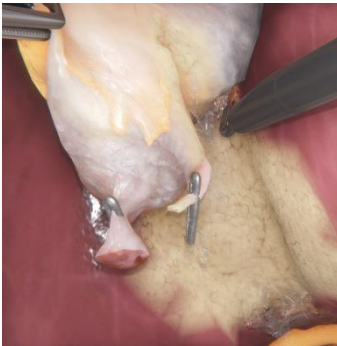Cystic Pedicle Dissection Situs Inversus Totalis (Guided/Unguided)

Safely identify and ligate the cystic duct and cystic artery.

Learning objectives:

- Safe and precise clip placement using the non-dominant hand
- Correct visualization and identification of anatomical structures
- Safe placement of clips on the cystic duct and the cystic artery while visualizing the lower blade of the instrument
- Correct use of tissue tension when dissecting the cystic duct and cystic artery
- Verification that vessels have been correctly clipped to ensure safe resection of the gallbladder

Resection

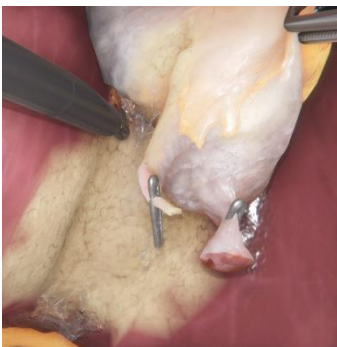

Gallbladder Resection (Guided/Unguided)

Safely resect the gallbladder from the liver, identifying the appropriate dissection plane.

Learning objectives:

- Correct retraction of the infundibulum of the gallbladder to apply tension to the dissection plane
- Identification of the appropriate dissection plane
- Dissection of the gallbladder from the liver starting at the infundibulum
- Correct use of traction and counter-traction during dissection
- Appropriate use of the unipolar electrode

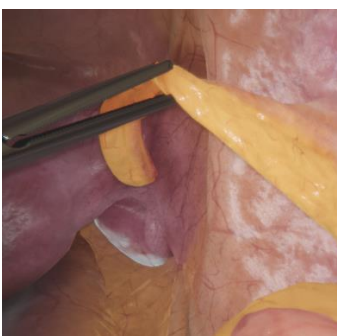

Gallbladder Resection Situs Inversus Totalis (Guided/Unguided)

Safely resect the gallbladder from the liver, identifying the appropriate dissection plane.

Learning objectives:

- Resection of the gallbladder from the liver bed using the non-dominant hand
- Correct retraction of the infundibulum of the gallbladder to apply tension to the dissection plane
- Identification of the appropriate dissection plane
- Dissection of the gallbladder from the liver starting at the infundibulum
- Correct use of traction and counter-traction during dissection
- Appropriate use of the unipolar electrode



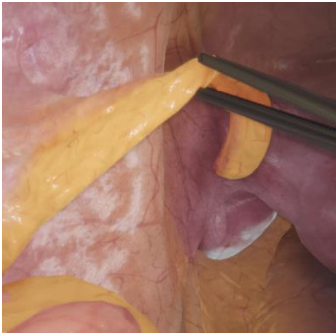Skeletonizing the Appendix (Guided/Unguided)

Safely expose the base of the appendix using sufficient tension and the correct resection techniques for different energy instruments.

Learning objectives:

- Safe dissection of the mesoappendix avoiding damage to neighboring structures
- Correct use of different resection techniques and instruments
- Work under laparoscopic vision
- Correct use of tissue traction and tension for a clean tissue separation

- Complete exposure and identification of the base of the appendix and the cecum



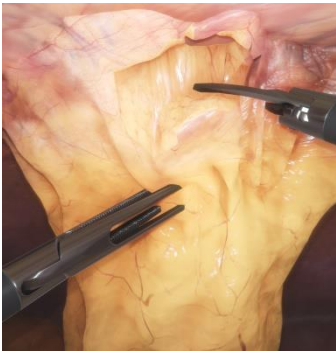
Skeletonizing the Appendix Situs Inversus Totalis (Guided/Unguided)

Safely expose the base of the appendix using sufficient tension and the correct resection techniques for different energy instruments.

Learning objectives:

- Safe and precise resection of the appendix with the non-dominant hand
- Safe dissection of the mesoappendix avoiding damage to neighboring structures
- Correct use of different resection techniques and instruments
- Work under laparoscopic vision
- Correct use of tissue traction and tension for a clean tissue separation
- Complete exposure and identification of the base of the appendix and the cecum

Adhesiolysis

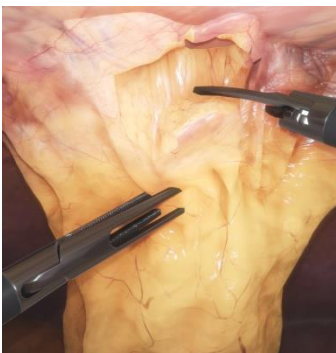


Incisional Hernia Site (Guided/Unguided)

Perform safe adhesiolysis and hernia reduction to create good visibility of the defect site.

Learning objectives:

- Optimal placement of working trocars
- Identification and visualization of hernia site
- Use of blunt and sharp dissection techniques to lyse adhesions
- Work under laparoscopic vision
- Application of correct tissue traction for tissue removal



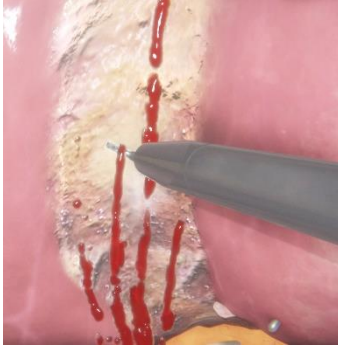Incisional Hernia Site Situs Inversus Totalis (Guided/Unguided)

Perform safe adhesiolysis and hernia reduction to create good visibility of the defect site.

Learning objectives:

- Safe adhesiolysis and hernia reduction using the non-dominant hand
- Optimal placement of working trocars
- Identification and visualization of hernia site
- Use of blunt and sharp dissection techniques to lyse adhesions
- Work under laparoscopic vision
- Application of correct tissue traction for tissue removal

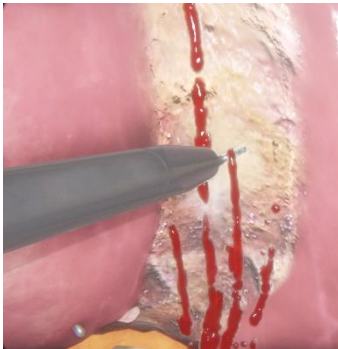Bleeding Control



Bleeding from Liver Bed, medium difficulty (Guided/Unguided)
Use a unipolar electrode to safely control liver bed hemorrhages.

Learning objectives:

- Correct identification of liver bed bleeding sources
- Efficient use of compression and coagulation to control liver bed bleeding
- Correct handling of electro-surgical instruments
- Use of the suction and irrigation instrument to establish visibility

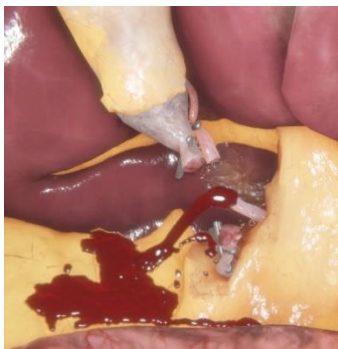

Bleeding from Liver Bed, medium difficulty Situs Inversus Totalis (Guided/Unguided)
Use a unipolar electrode to safely control liver bed hemorrhages.

Learning objectives:

- Safe control of liver bed hemorrhages using the non-dominant hand
- Correct identification of liver bed bleeding sources
- Efficient use of compression and coagulation to control liver bed bleeding
- Correct handling of electro-surgical instruments
- Use of the suction and irrigation instrument to establish visibility

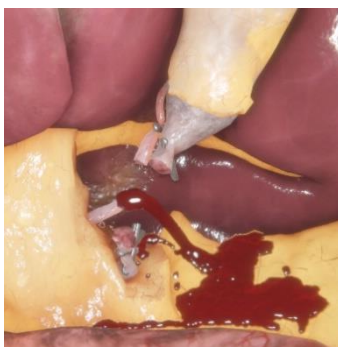
Complication Handling



Management of a Vascular Injury (Guided/Unguided)
Efficiently identify and manage bleeding from the cystic artery.

Learning objectives:

- Correct identification of the source of bleeding
- Efficient use of compression, suction and safe clip placement
- Management of a surgical complication in a calm, deliberate and efficient manner

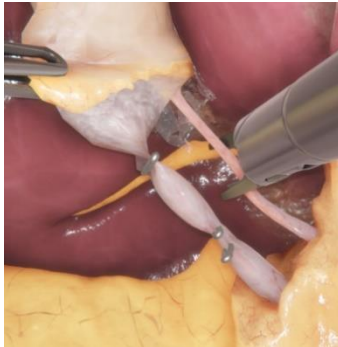


Management of a Vascular Injury Situs Inversus Totalis (Guided/Unguided)
Efficiently identify and manage bleeding from the cystic artery.

Learning objectives:

- Safe and efficient clip placement and bleeding control using the non-dominant hand
- Correct identification of the source of bleeding
- Efficient use of compression, suction and safe clip placement
- Management of a surgical complication in a calm, deliberate and efficient manner

Free Training

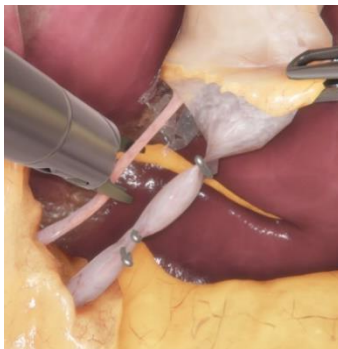


Cholecystitis (Unguided)

Perform a full Cholecystectomy by selecting the correct patient, trocar and OR team positions and establishing the critical view of safety using different dissection techniques, then carefully dissecting the gallbladder from the liver bed.

Learning objectives:

- Retraction of the gallbladder to expose the hepatocystic triangle
- Use of different blunt and sharp dissection techniques with a surgical sponge holder, dissecting and grasping forceps and a unipolar electrode
- Obtainment of the critical view of safety
- Safe application of clips and division of the cystic duct and artery
- Use of clips to control vessel bleeding
- Resection of the gallbladder from the liver bed with a unipolar electrode



Cholecystitis Situs Inversus Totalis (Unguided)

Perform a full Cholecystectomy by selecting the correct patient, trocar and OR team positions and establishing the critical view of safety using different dissection techniques, then carefully dissecting the gallbladder from the liver bed.

Learning objectives:

- Performing a complete Cholecystectomy in situs inversus totalis with the non-dominant hand as the main operating hand
- Retraction of the gallbladder to expose the hepatocystic triangle
- Use of different blunt and sharp dissection techniques with a surgical sponge holder, dissecting and grasping forceps and a unipolar electrode
- Obtainment of the critical view of safety
- Safe application of clips and division of the cystic duct and artery
- Use of clips to control vessel bleeding
- Resection of the gallbladder from the liver bed with a unipolar electrode

VirtaMed LaparoS™

Module descriptions – Gynecological Laparoscopy v1.0

Learning objectives

- Selection of correct patient position and trocar placement according to the simulated procedure
- Correct identification of important anatomical landmarks and pathologies
- Efficient and safe use of laparoscopic instruments, including suction and irrigation device, monopolar and bipolar instruments, sterilization clip applicator and more
- Learning different resection and dissection techniques as well as bleeding control

Condensed training approach

The LaparoS™ training concept is focused on short sequences teaching transferable key skills. Each sequence takes place in a realistic environment and can be repeated according to the needs of the trainee until proficiency level is reached and stabilized, resulting in higher motivation and accelerated outcomes.

Instruments



Laparoscope



Atraumatic Grasper / Bipolar Kelly Grasper / Monopolar Kelly Grasper / Monopolar Electrode / Sterilization Clip Applicator / Scissors / Suction and Irrigation Device

Contact the VirtaMed team to find out more:

+41 44 500 96 90

sales@virtamed.com

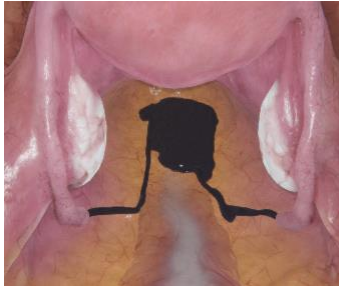
Guided/Unguided variant

For most of the training cases, there are two variants: guided and unguided training.

Guided: the current task to be accomplished is always displayed on the interface. Every step is guided with visual elements.

Unguided: The list of tasks to be accomplished is available on user request during the training. There are no guidance elements during the procedure or information messages.

Diagnostic Laparoscopy



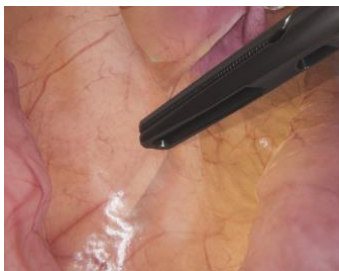Tubal Patency Test (Guided/Unguided)

Tubal sterility is suspected in a 34 year old nulliparous patient. Perform a diagnostic laparoscopy visualizing the key anatomical landmarks followed by a tubal patency test through injection of Methylene blue dye.

Learning objectives:

- Perform a clockwise diagnostic laparoscopy of the peritoneal cavity
- Adjustment of the patient's position to get a clear view of the operative field
- Identification of the key anatomical landmarks of the female pelvis
- Safe manipulation of the adnexa and lifting of the uterus to visualize the dye flow out from the fallopian tubes

Anatomical Concepts

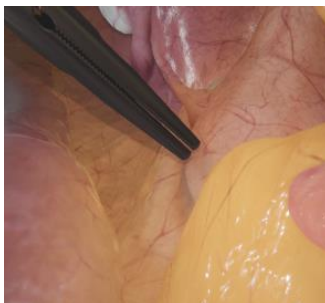

Ureter Identification (left) (Guided/Unguided)

Safely identify and trace the course of the left ureter crossing over the pelvic brim and inside the pouch of Douglas. Use blunt instruments to provoke peristalsis.

Learning objectives:

- Memorization of the key anatomical landmarks of the female pelvis
- Correct manipulation of the uterus to prepare for visualization of the left ureter
- Safe identification and following of the course of the left ureter
- Usage of placed ureteral stents to support the correct identification of the ureter



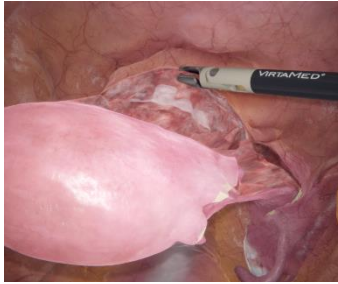
Ureter Identification (right) (Guided/Unguided)

Safely identify and trace the course of the right ureter crossing over the pelvic brim and inside the pouch of Douglas. Use blunt instruments to provoke peristalsis.

Learning objectives:

- Memorization of the key anatomical landmarks of the female pelvis
- Correct manipulation of the uterus to prepare for visualization of the right ureter
- Safe identification and following of the course of the right ureter
- Usage of placed ureteral stents to support the correct identification of the ureter

Exposure of Structures



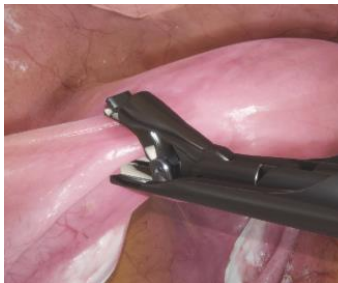Vesicouterine Fold Dissection (Guided/Unguided)

Safely identify the vesico-uterine junction and carefully dissect the vesicouterine fold in preparation for total laparoscopic hysterectomy.

Learning objectives:

- Correct positioning of the uterine manipulator to establish optimal visibility
- Identification of the correct dissection plane
- Careful opening of the peritoneal layer using scissors, blunt dissection and bipolar coagulation
- Safe identification and retraction of the bladder fold

Clipping and Ligation

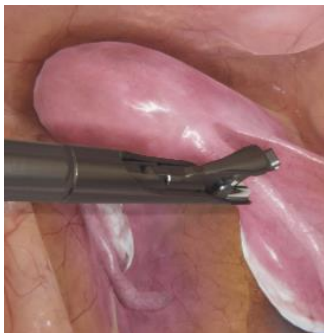

Tubal Sterilization (left) (Guided/Unguided)

A 42 year old women with 3 children presents with the wish for permanent postpartum sterilization. Ligation of the left fallopian tube will be performed using a sterilization clip.

Learning objectives:

- Correct retraction of the left fallopian tube to prepare for ligation
- Safe placement of a sterilization clip in the correct location
- Capturing of an image to verify correct clip placement

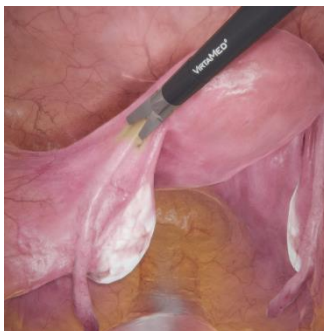

Tubal Sterilization (right) (Guided/Unguided)

A 42 year old women with 3 children presents with the wish for permanent postpartum sterilization. Ligation of the right fallopian tube will be performed using a sterilization clip.

Learning objectives:

- Correct retraction of the right fallopian tube to prepare for ligation
- Safe placement of a sterilization clip in the correct location
- Capturing of an image to verify correct clip placement



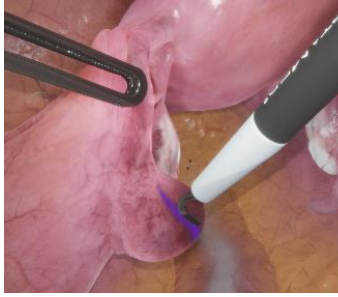
Tubal Sterilization - Bipolar Coagulation (Guided/Unguided)

A 45-year-old woman expresses her wish for permanent post-partum sterilization. Sterilization of both fallopian tubes will be performed using bipolar coagulation.

Learning objectives:

- Correct retraction of the fallopian tube to prepare for ligation
- Safe coagulation of the first 3 cm of the tubal isthmus on both sides
- Cutting the coagulated area with scissors (optional)
- Capturing an image on both sides to verify complete ligation

Resection

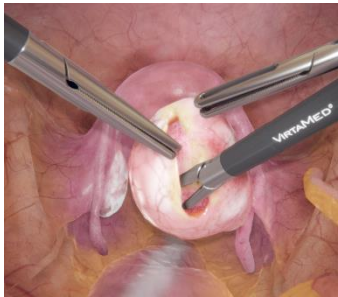

Ectopic Pregnancy - Salpingotomy (Guided/Unguided)

A 33 year old woman presents with severe abdominal pain. Prior examination revealed a positive pregnancy test. Ultrasound exams showed an enlarged left fallopian tube and a significant amount of fluid in the pouch of Douglas. Suspicion of ectopic pregnancy in the left fallopian tube is an indication for laparoscopy. Safely perform a salpingotomy to extract the ectopic pregnancy and preserve the fallopian tube, manage the bleeding encountered and clean the operative field to enable a speedy healing process.

Learning objectives:

- Evacuation of the hemoperitoneum to establish a clear view of the operative field
- Visualization of the location of ectopic pregnancy
- Identification of the area for incision at the anti-mesosalpingeal border
- Avoiding causing damage to surrounding structures during surgical treatment of the ectopic pregnancy
- Safe extraction of the trophoblast using aspiration and grasping forceps

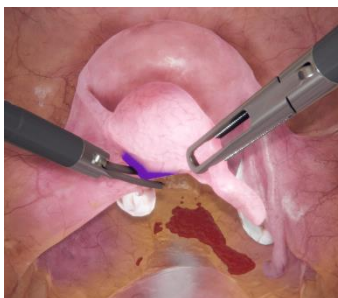


Cystectomy - Ovarian Cyst (Guided/Unguided)

A 35 year old women presents with lower abdominal pain and a persistent ovarian cyst on the right side. Safe and complete removal of the ovarian cyst will need to be performed using blunt dissection and peeling movements.

Learning objectives:

- Careful opening of the ovary to remove the cyst
- Safe removal of the cyst using blunt dissection and peeling movements
- Cleaning of the operative field and management of minor bleeders

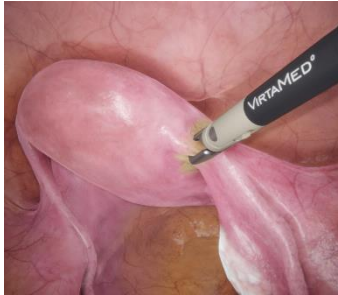

Salpingectomy (left) (Guided/Unguided)

A 35 year old women presents with severe pain in the left lower pelvis. An ectopic pregnancy is suspected during ultrasound examination. The patient has a history of infertility and a salpingectomy of the left fallopian tube is proposed to avoid further complications.

Learning objectives:

- Identification and visualization of the ovarian vasculature to prevent injuries
- Putting adequate traction onto the fallopian tube during resection
- Safe transection of the mesosalpinx using bipolar coagulation and cutting

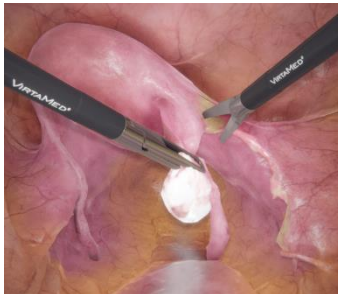

Treatment of Adnexa - without Adnexectomy (Guided/Unguided)

A 30 year old women with a history of endometriosis treatment presents for surgery because of significant pain caused by uterine adenomyosis. A total laparoscopic hysterectomy with preservation of the adnexa is planned.

Learning objectives:

- Correct positioning of the uterus to avoid ureter damage
- Safe identification of the ureters with peristalsis on both sides
- Preparation of the adnexa for hysterectomy without performing adnexectomy: coagulation and dissection of the ovarian ligaments as well as fallopian tubes and round ligaments staying close to the uterine insertion
- Ensuring not to damage any surrounding tissues



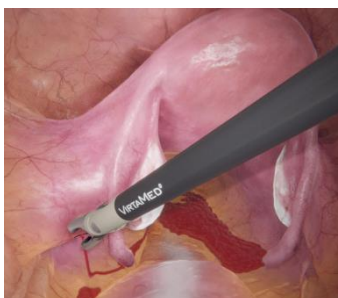Treatment of Adnexa - with Adnexectomy (Guided/Unguided)

A 62 year old women has asked for a total laparoscopic hysterectomy with adnexectomy to be performed after a suspect mass in the cervix has been detected with MRT. Adnexectomy in preparation for subsequent hysterectomy shall be performed on both sides, making sure to safely coagulate and transect the round ligaments first to mobilize the uterus.

Learning objectives:

- Correct positioning of the uterus to avoid ureter damage
- Safe identification of the ureters with peristalsis on both sides
- Safe division of the IP ligaments using bipolar coagulation and scissors to prepare the adnexa for removal with hysterectomy
- Coagulation and transection of the broad and the round ligaments to achieve good mobilization of the uterus

Bleeding Control

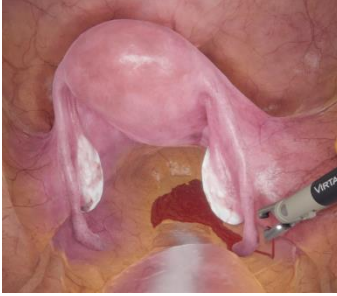

Ovarian Artery Bleeding (left) (Guided/Unguided)

The left IP ligament has been accidentally harmed during adnexectomy without prior coagulation. The bleeding from the ovarian artery needs to be controlled safely without harming surrounding structures such as the ureter.

Learning objectives:

- Identification and compression of the source of bleeding
- Establishing a safe distance between the underlying ureter and the IP ligament
- Safe coagulation of the bleeder using bipolar coagulation and cleaning of the operative field

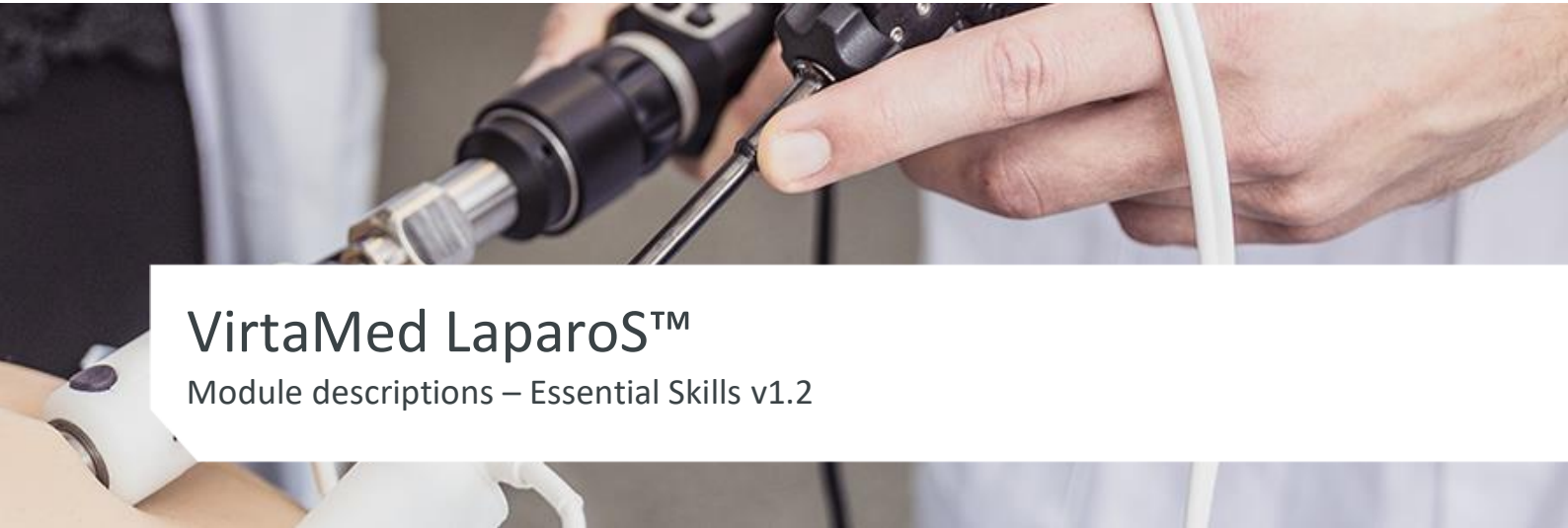

Ovarian Artery Bleeding (right) (Guided/Unguided)

The right IP ligament has been accidentally harmed during adnexectomy without prior coagulation. The bleeding from the ovarian artery needs to be controlled safely without harming surrounding structures such as the ureter.

Learning objectives:

- Identification and compression of the source of bleeding
- Establishing a safe distance between the underlying ureter and the IP ligament
- Safe coagulation of the bleeder using bipolar coagulation and cleaning of the operative field



VirtaMed LaparoS™

Module descriptions – Essential Skills v1.2

Learning objectives

- Acquisition of basic laparoscopic skills of camera navigation
- Development of ambidextrous motor skills
- First handling of the clip applicator and scissors in a virtual environment, including acquisition of control and precision in cutting
- First handling of the needle holder in a virtual environment

Condensed training approach

The LaparoS™ Essential Skills module is focused on abstract exercises teaching transferable key skills. Each sequence takes place in an abstract environment and can be repeated according to the needs of the trainee until proficiency level is reached and stabilized, resulting in higher motivation and accelerated outcomes.

Instruments



Laparoscope



Atraumatic Grasper / Clip Applicator / Scissors / Suction Device



Needle Holder

Contact the VirtaMed team to find out more:

+41 44 500 96 90

sales@virtamed.com

Camera Navigation



Image Centering & Horizon Control


(0/30°, Front/Back working position)

Learning goals:

- Navigating with the camera using the 0 or 30° optic to visualise all important areas of the laparoscopic anatomy and train image centering
- Becoming familiar with the concept of image horizon control in relation to camera rotation and distance

Objectives:

- Entering the virtual environment with the laparoscope through the highlighted portal
- Looking at the target and centering it with proper horizon and distance
- Finding all the target positions



Periscoping

(30°, Front/Back working position)

Learning goals:

- Navigating with the camera to visualise all important areas of the laparoscopic anatomy, and train image centering and optic angle adjustment
- Improving spatial recognition
- Becoming familiar with the concept of horizon control in relation to camera rotation, distance and optic angles

Objectives:

- Entering the virtual environment with the laparoscope through the highlighted portal
- Looking at the target and centering it with proper horizon, distance and optic angle
- Finding all the target positions

Hand-eye Coordination




Image Centering & Lifting

(0/30°, Left/Right dominant hand, Front/Back working position)

Learning goals:

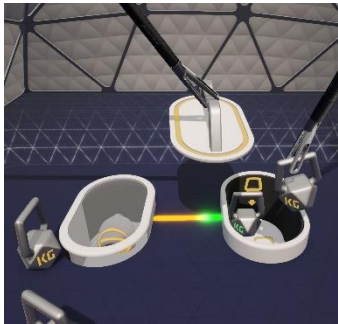
- Navigating with the camera while using the non-dominant hand and handling a forceps with the dominant hand
- Developing efficient ambidextrous skills with a basic hand tool using laparoscopic image control, with the simultaneous demands of deliberate task planning

Objectives:

- Entering the virtual environment with the laparoscope through the highlighted portal
- Inserting one instrument through the second highlighted portal
- Lifting objects with the instrument to find the target

- Centering the target with proper horizon and distance once it is visible
- Finding all the target positions

Bimanual Coordination



Collect the Weights


(0/30°, Front/Back working position)

Learning goals:

- Triangulation using two instruments simultaneously
- Manipulating the weights safely without dropping them outside the target area
- Learning how to safely pass an object from one instrument to the other

Objectives:

- Entering the virtual environment with the laparoscope through the highlighted portal
- Setting the view at a proper location
- Inserting instruments through the highlighted portals
- Using the instruments to lift the lid with one hand and grasp one of the weights with the other hand while ensuring correct triangulation
- Transferring the weights into the hole to push the left platform up and free the target



Grasping & Bimanual Coordination

(0/30°, Front/Back working position)

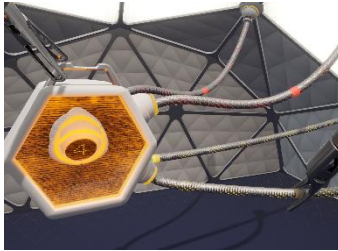
Learning goals:

- Handling two instruments simultaneously
- Developing efficient ambidextrous skills with the simultaneous demands of deliberate task planning

Objectives:

- Entering the virtual environment with the laparoscope through the highlighted portal
- Setting the view at a proper location
- Inserting instruments through the highlighted portals
- Using two instruments to have the correct orientation of the key and unlock the next target position
- Finding all the target positions

Clipping



Clipping


(0/30°, Left/Right dominant hand, Front/Back working position)

Learning goals:

- Handling two instruments simultaneously
- Training proper tension application prior to placing a clip

Objectives:

- Entering the virtual environment with the laparoscope through the highlighted portal
- Setting the view at a proper location
- Inserting instruments through the highlighted portals
- Tensioning of the tubes and placing clips within the marked areas



Clipping - Crossing Instruments

(0/30°, Left/Right dominant hand, Front/Back working position)


Learning goals:

- Handling two instruments simultaneously
- Training proper tension application prior to placing a clip while ensuring proper vision of the region of interest with the enhanced difficulty of having instruments crossed

Objectives:

- Entering the virtual environment with the laparoscope through the highlighted portal
- Setting the view at a proper location
- Inserting instruments through the highlighted portals
- Tensioning of the tubes and placing clips within the marked areas

Cutting



Cutting

(0/30°, Left/Right dominant hand, Front/Back working position)

Learning goals:

- Handling two instruments simultaneously
- Training proper tension application prior to cutting

Objectives:

- Entering the virtual environment with the laparoscope through the highlighted portal
- Setting the view at a proper location
- Inserting instruments through the highlighted portals
- Tensioning of the tubes and cutting within the marked areas



Cutting - Crossing Instruments


(0/30°, Left/Right dominant hand, Front/Back working position)

Learning goals:

- Handling two instruments simultaneously
- Training proper tension application prior to cutting while ensuring proper vision of the region of interest with the enhanced difficulty of having instruments crossed

Objectives:

- Entering the virtual environment with the laparoscope through the highlighted portal
- Setting the view at a proper location
- Inserting instruments through the highlighted portals
- Tensioning of the tubes and cutting within the marked areas



Straight Cutting


(0/30°, Left/Right dominant hand, Front/Back working position)

Learning goals:

- Handling two instruments simultaneously
- Training proper tension application prior to cutting while ensuring proper cutting precision
- Learning how to cut a straight line at a precise depth

Objectives:

- Entering the virtual environment with the laparoscope through the highlighted portal
- Setting the view at a proper location
- Inserting instruments through the highlighted portals
- Tensioning the tissue and cutting within the marked areas



Circular Cutting – Easy


(0/30°, Left/Right dominant hand, Front/Back working position)

Learning goals:

- Handling two instruments simultaneously
- Training proper tension application prior to cutting while ensuring proper cutting precision
- Learning how to cut a precise shape at a precise depth

Objectives:

- Entering the virtual environment with the laparoscope through the highlighted portal
- Setting the view at a proper location
- Inserting instruments through the highlighted portals
- Tensioning the tissue and cutting in between two circle lines



Circular Cutting – Difficult

(0/30°, Left/Right dominant hand, Front/Back working position)

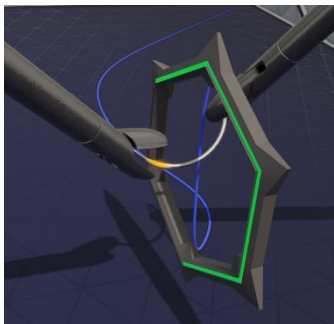
Learning goals:

- Handling two instruments simultaneously
- Training proper tension application prior to cutting while ensuring proper cutting precision
- Learning how to cut a precise shape at a precise depth

Objectives:

- Entering the virtual environment with the laparoscope through the highlighted portal
- Setting the view at a proper location
- Inserting instruments through the highlighted portals
- Tensioning the tissue and following the circle line

Suturing



Needle Passing


(0/30°, Left/Right dominant hand, Front/Back working position)

Learning goals:

- Developing efficient ambidextrous skills by passing the needle from the dominant hand to the non-dominant hand and vice versa
- Training proper needle passing skills

Objectives:

- Entering the virtual environment with the laparoscope through the highlighted portal
- Setting the view at a proper location
- Inserting the needle holders through the highlighted portals
- Grasping the needle on the highlighted mark with the dominant hand and passing it through the active ring without touching the edges
- Grasping the tip of the needle on the highlighted mark with the non-dominant hand and gently pulling the needle to pass the thread through the ring
- Repeating the task with the rest of the rings
- Using the needle holders to obtain the correct orientation of the needle and unlock the box



Needle Insertion

(0/30°, Left/Right dominant hand, Front/Back working position)

Learning goals:

- Developing efficient ambidextrous skills by passing the needle from the dominant hand to the non-dominant hand and vice versa
- Becoming familiar with needle tip orientation when performing a suture

Objectives:

- Entering the virtual environment with the laparoscope through the highlighted portal

- Setting the view at a proper location
- Inserting the needle holders through the highlighted portals
- Grasping the needle on the highlighted mark with the dominant hand and inserting the needle tip through the active ring at a 90° angle without touching the edges
- Grasping the tip of the needle on the highlighted mark with the non-dominant hand and gently pulling the needle to pass the thread through the ring
- Repeating the task with the rest of the rings
- Using the needle holders to obtain the correct orientation of the needle and unlock the box

© VirtaMed AG 2021. All rights reserved.

No part of this document may be reproduced or transmitted in any form or by any means, electronic or otherwise, for any purpose, without the express written permission of VirtaMed AG. Every effort has been made to ensure that the information in this document is accurate. VirtaMed AG is not responsible for printing or clerical errors. Information in this document is subject to change without notice.

V2109